

# Immediate Implantation and Immediate Loading with CAMLOG for Edentulous Patient

泰康拜博口腔  
Taikang Bybo Dental

Hongqiang Li (www.21188617@qq.com)  
Taikang Bybo Dental

## BACKGROUND

The patient reported that all of his teeth successively fell out over a period of 10 years and he didn't receive any treatment. Now, the patient is requesting dental restoration due to difficulty chewing

Previously healthy, denied a history of major illness or infectious disease.

Maxilla: 11, 21, 12, 15, 17 grade III mobility, 18 grade II mobility, 16 residual root, the remaining teeth are missing. Keratinized gingiva shows band-like distribution.

Mandible: 33, 36 residual roots, 34, 35, 37 grade III mobility, 38 grade II mobility, the remaining teeth are missing. Keratinized gingiva shows band-like distribution.  
Diagnosis: Partial edentulism; chronic periodontitis

## AIM

Tooth extraction and debridement, incision and ligation, alveolar ridge repair, fixation of guide plate

## MATERIALS&METHODS

Tooth extraction and debridement, incision and ligation, alveolar ridge repair, fixation of guide plate

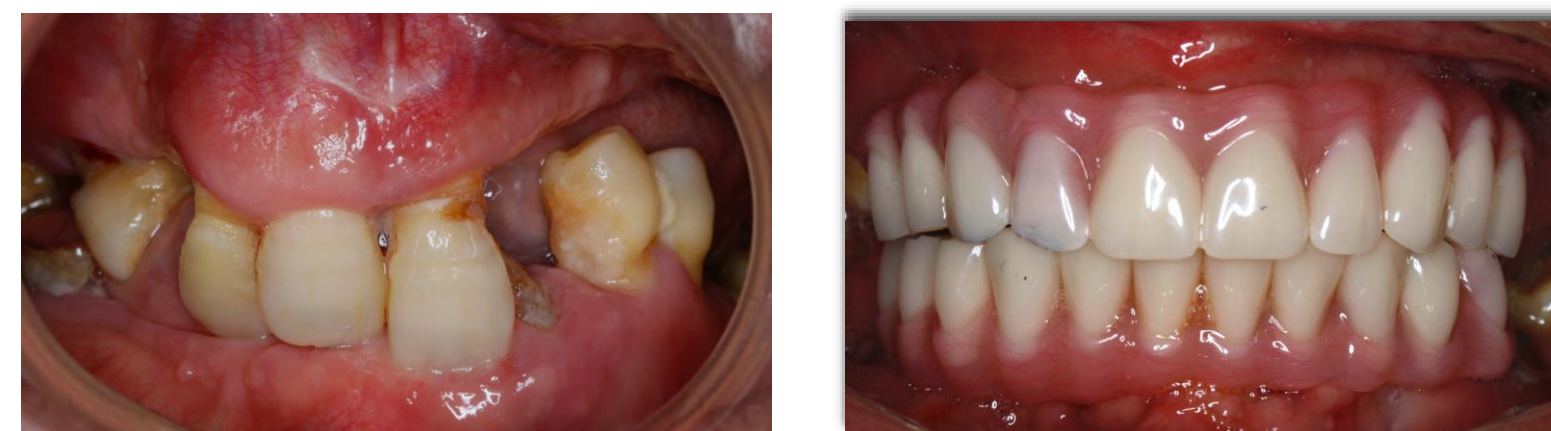Maxilla: Examine the maxillary sinus anterior wall

Mandible: Locate the mental foramen  
Locate and determine the orientation, examine the integrity of the four walls  
Expand the hole, prepare the implant, insert the multi-unit abutment with a torque of 35N, and verify parallelism

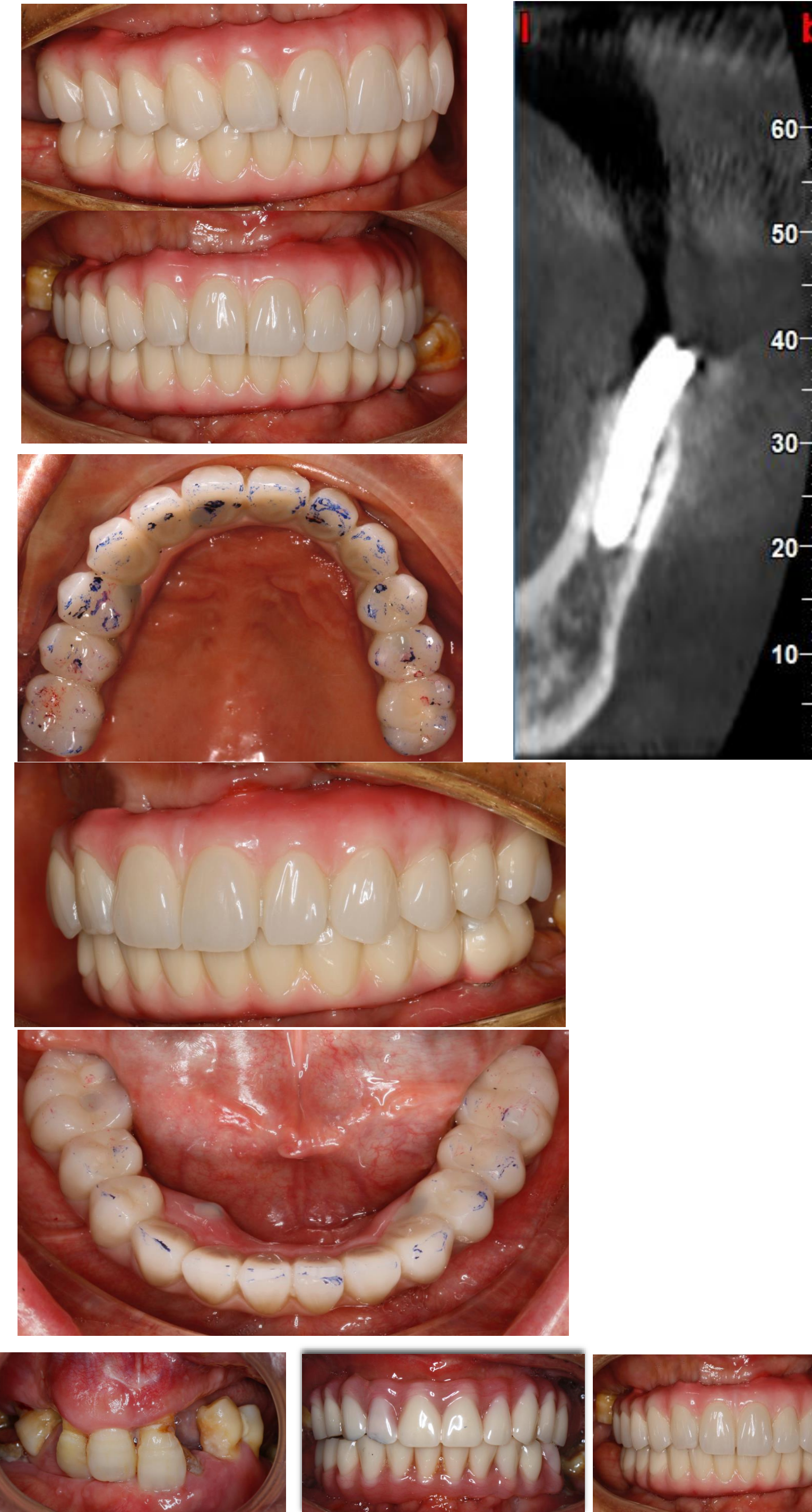
Use the multi-unit abutment driver to carry bite registration to determine relationship and to mount the face-bow

Get the dentures on the same day  
Stage 2 impression: Use the adjusted temporary denture to transfer the relationship and verify passive fit:  
Trial framework

Photo example:



## RESULTS



## CONCLUSIONS

Final prosthesis: Pure titanium framework + polymerized ceramic restoration base: Boat bottom design

Occlusion: intercuspal occlusion